Diagnosis of inflammatory diseases of the paranasal sinuses using diaphanoscopy

E.O. Bryanskaya[1*], I.N. Makovik[1,2], A.G. Bukin[3], O.A. Bibikova[2], B.M. Shuraev[4], O. Minet[5], U. Zabarylo[6], A.V. Dunaev[1], V.G. Artyushenko[2]

[1]Orel State University named after I.S. Turgenev, Orel, Russia
[2]art photonics GmbH, Berlin, Germany
[3]Institute of Engineering Physics, Serpukhov, Russia
[4]Diagnostic Medical Center "MediScan", Orel, Russia
[5]Charité Universitätsmedizin Berlin, Berlin, Germany
[6]Charité – Universitätsklinikum Berlin, Berlin, Germany

***E-mail: bryanskayae@mail.ru** **www.bmecenter.ru/en**

Introduction

The pathologies of the paranasal sinuses occupy a leading place among all diseases in otolaryngology (**more than 50%**).
The diagnostic methods used today have disadvantages that the digital diaphanoscopy method haven't.
Advantages of digital diaphanoscopy: simplicity, quick analysis, safety (no radiation), portability, non-invasive, painlessness

The aim of research

- ✓ To evaluate the applicability of the digital diaphanoscopy method to investigate diseases of paranasal sinuses ;
- ✓ to identify factors that influence on the diagnostics result;
- ✓ to justify the medical and technical requirements for the instrument by a signal simulation.

Experimental method and equipment



Scheme of the experimental setup without (a) and with a protective case (b)

LED-applicator has wavelengths:
- ✓ 650 nm
- ✓ 850 nm

Camera: UI-3240CP Rev.2
Quantum efficiency:
- ✓ 75% (650 nm)
- ✓ 45% (850 nm)

1T MRI Scanner of the Magnetom series (Siemens)

Diagnostics methods: digital diaphanoscopy and magnetic resonance imaging (MRI)
20 healthy volunteers
15 patients with pathologies of the paranasal sinuses

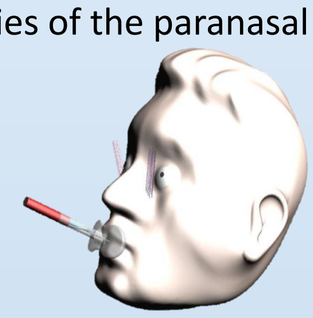

Results and Discussion

MRI study examples (left) and examples of registered and processed images (right) at exposure time 20.7 ms for 650 nm (a), 850 nm (b) and combination 650 and 860 nm (c) radiation sources

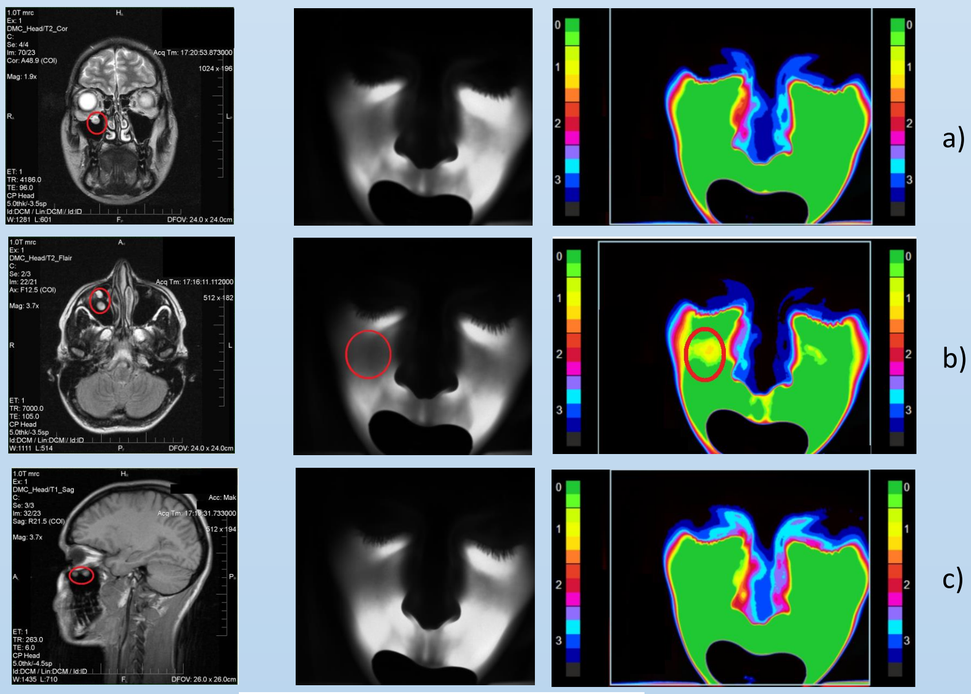

Patient 1 (female)

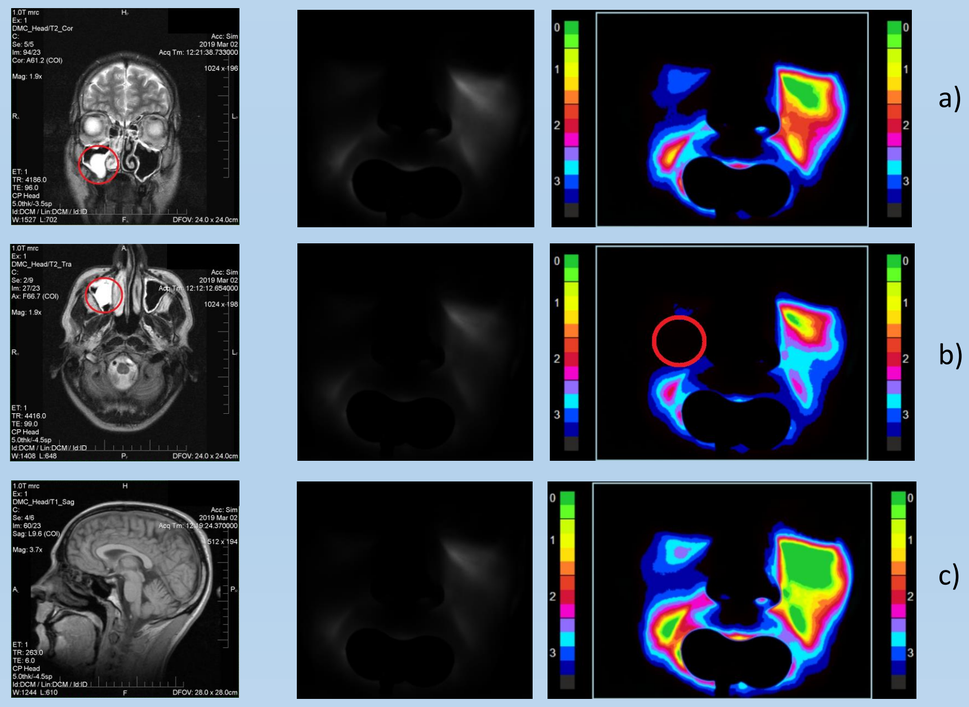

Patient 2 (male)

- ✓ In 4 patients out of 15, cysts were found in the right sinuses in two studies.

The simulation results of probing signal passing through the maxillary sinus of a female without pathology (a) and with a cyst (b) for 650 nm (top) and 850 nm (bottom)

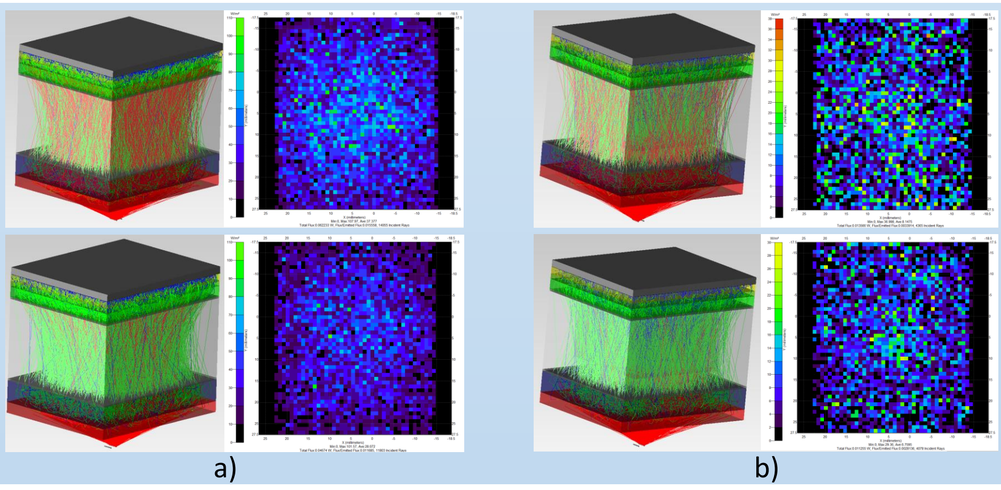

The simulation results of probing signal passing through the maxillary sinus of a male without pathology (a) and with a cyst (b) for 650 nm (top) and 850 nm (bottom)

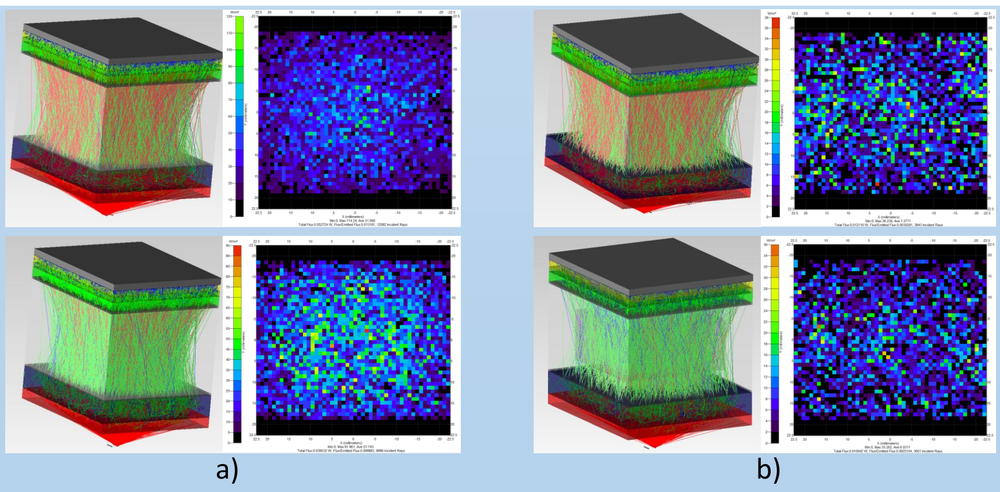

The dependence of the power on the detector of camera for different wavelengths depending on the hypoderm thicknesses and the presence of pathologies in the sinuses

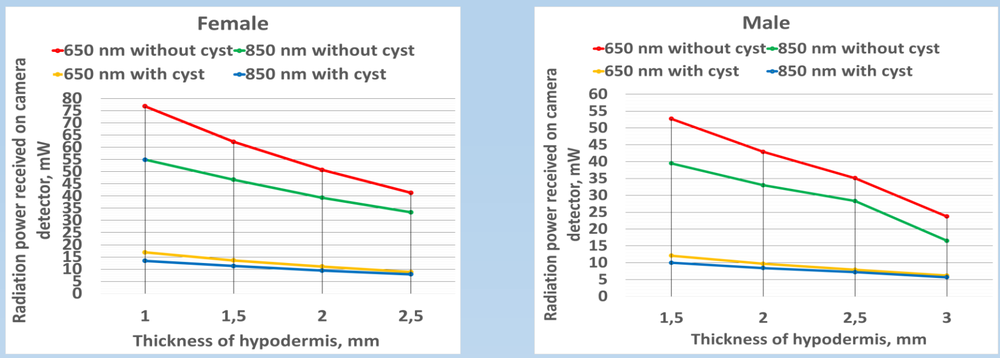

Acknowledgments

To volunteers and to patients of the Diagnostic Medical Center "MediScan", Orel, Russia.
The work was supported by the grant of the President of the Russian Federation for state support of young Russian scientists № МК-2634.2019.8.

Conclusion

- ✓ The experimental results demonstrate that the digital diaphanoscopy has potential to separate normal and pathological conditions.
- ✓ The decrease in the radiation power has a more pronounced character at 850 nm wavelength both for female and male, but depends on anatomical and gender features.